

# IMPLANTOLOGIA

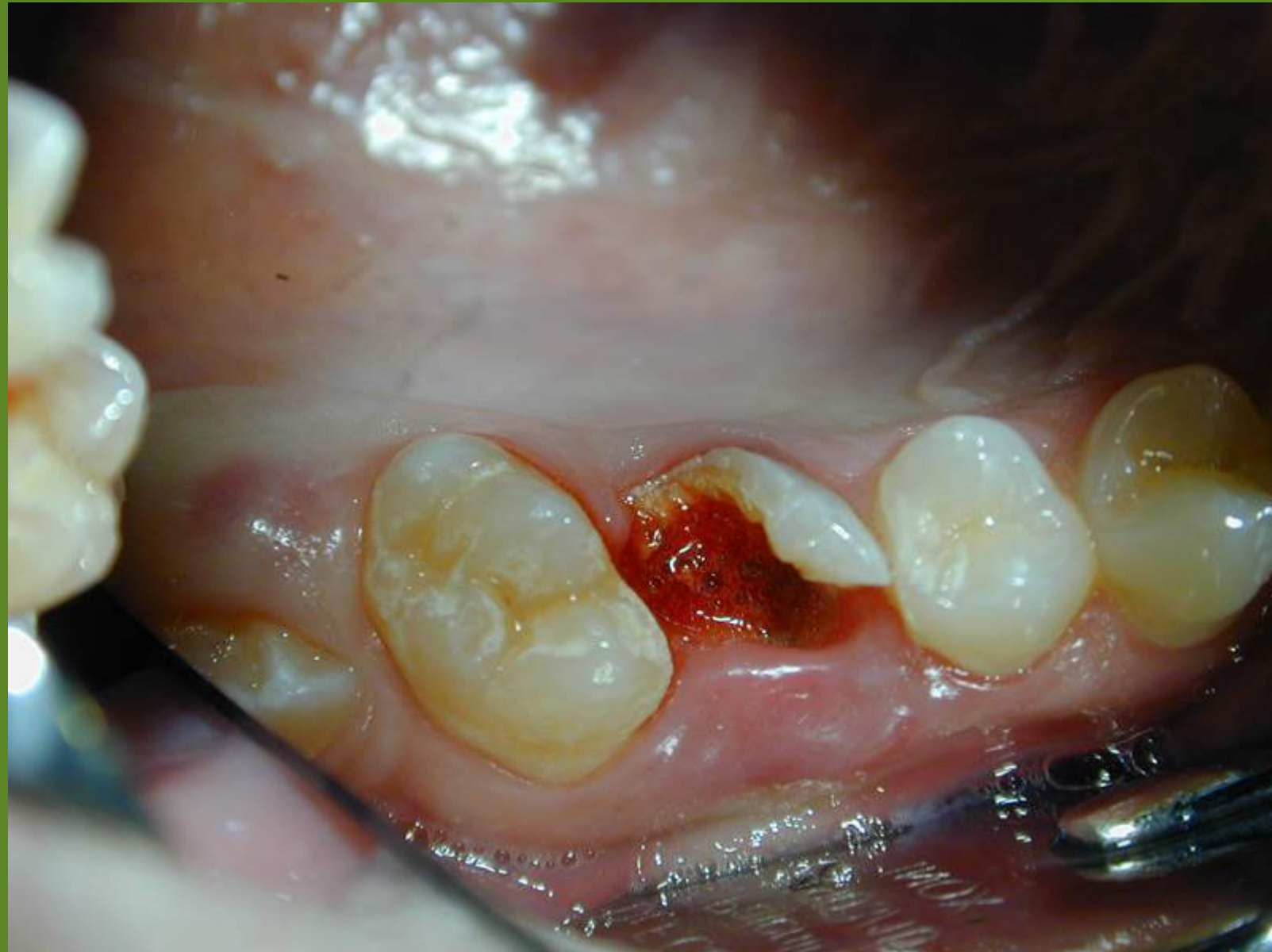## CAUSE PERDITA ELEMENTO DENTALE

- CARIE DESTRUENTE
- RIASSORBIMENTO RADICOLARE
  - MALATTIA PARODONTALE
  - TRAUMI VARI

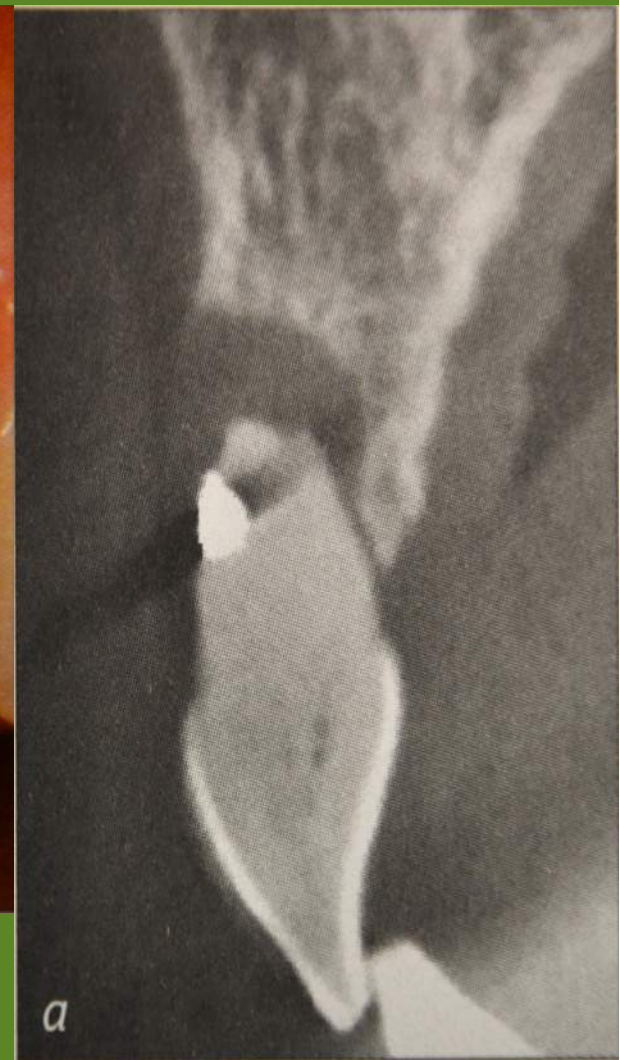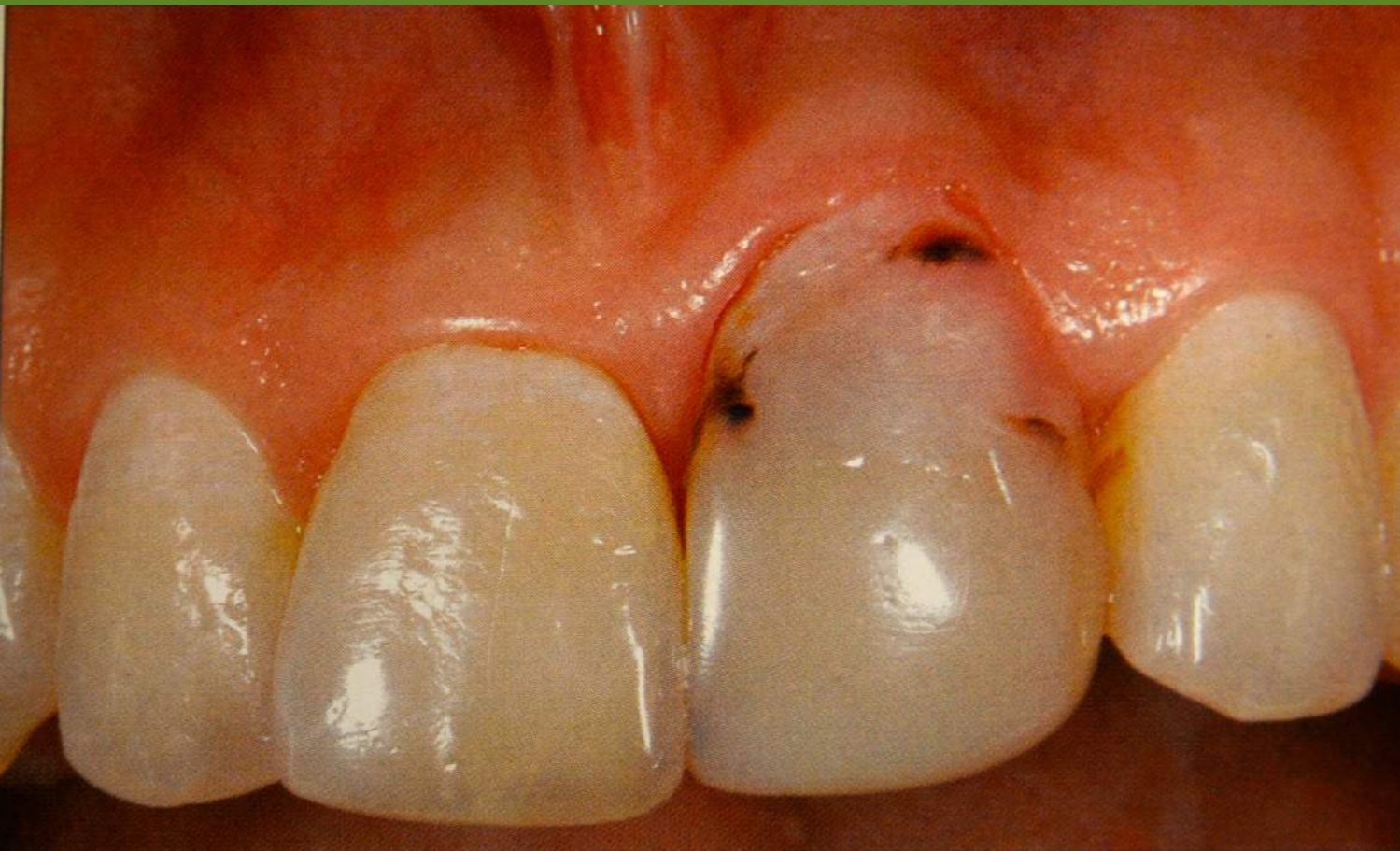# PRIMA VISITA

- ANAMNESI DEL PAZIENTE
- ESAME CLINICO
- ESAMI RADIOLOGICI

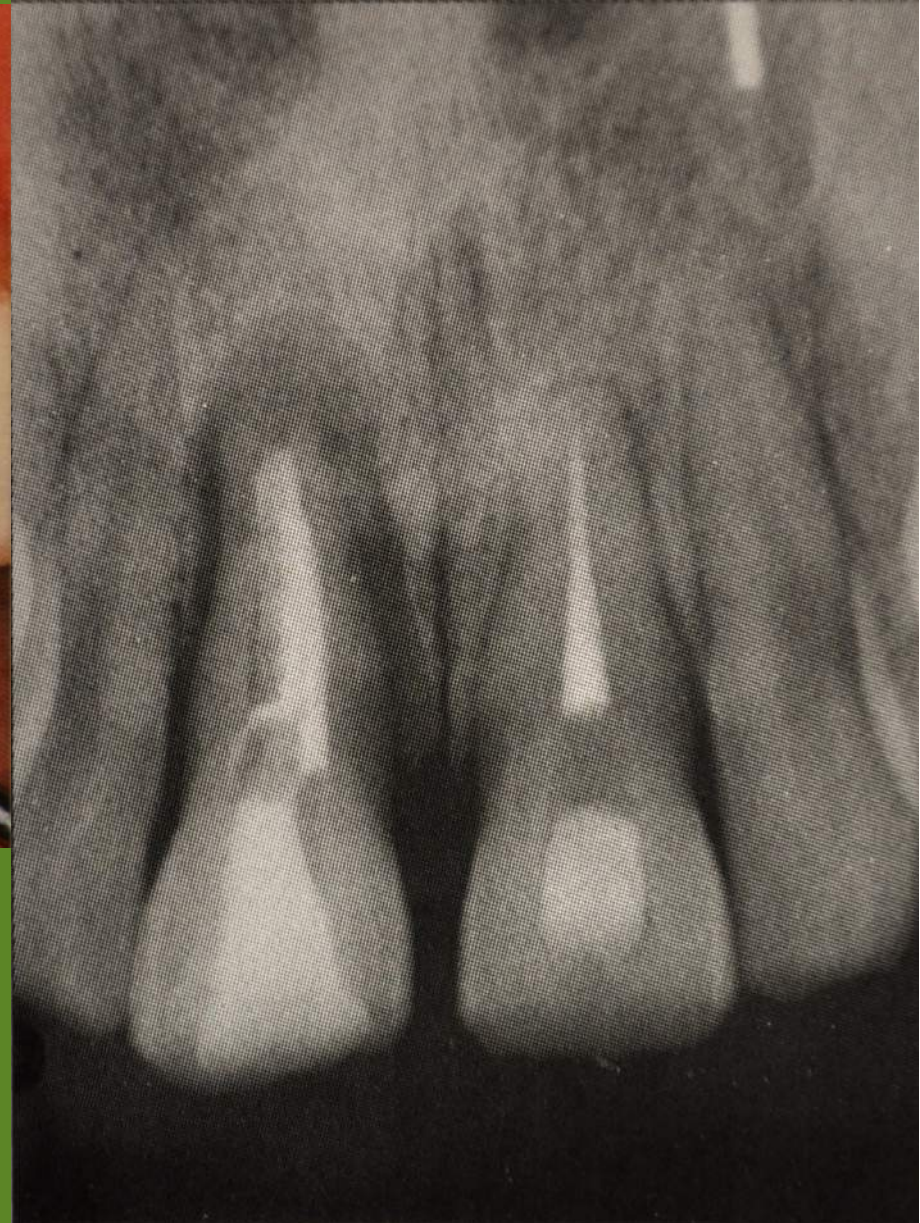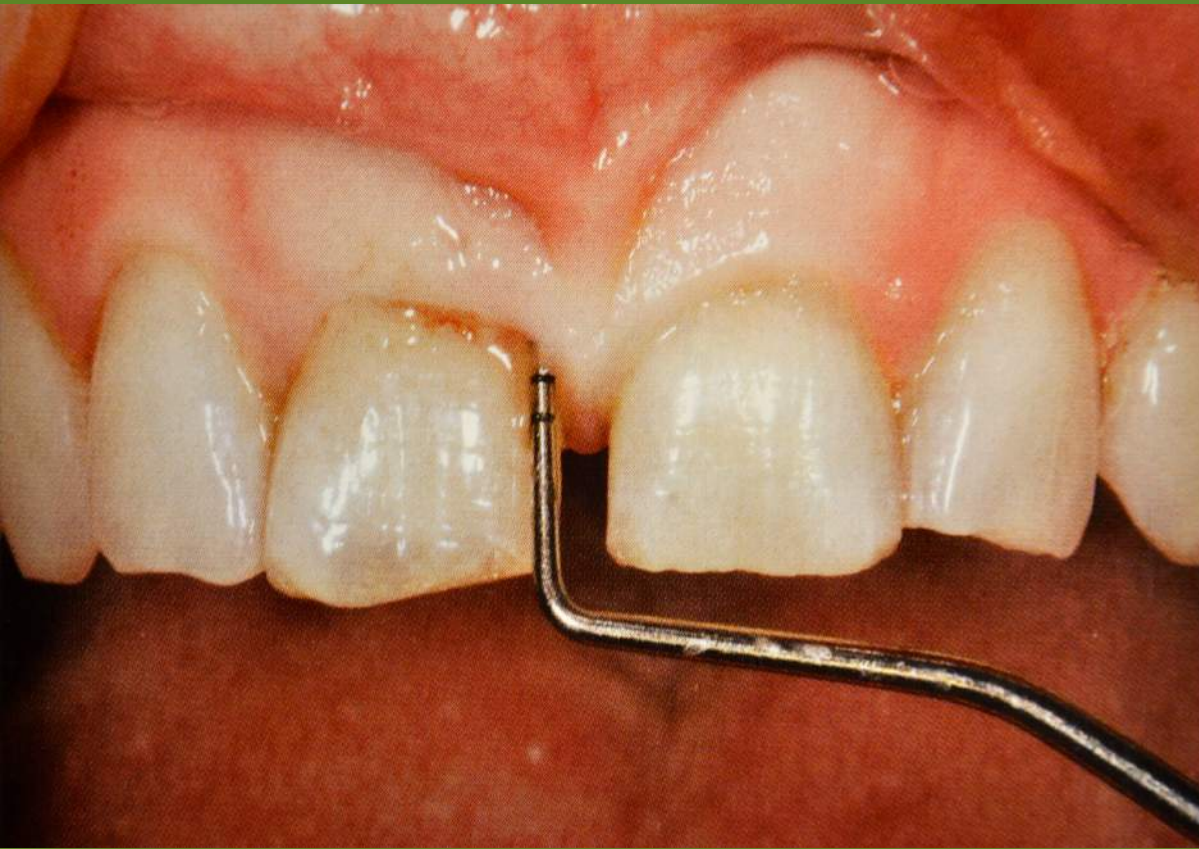
# CARIE DESTRUENTE



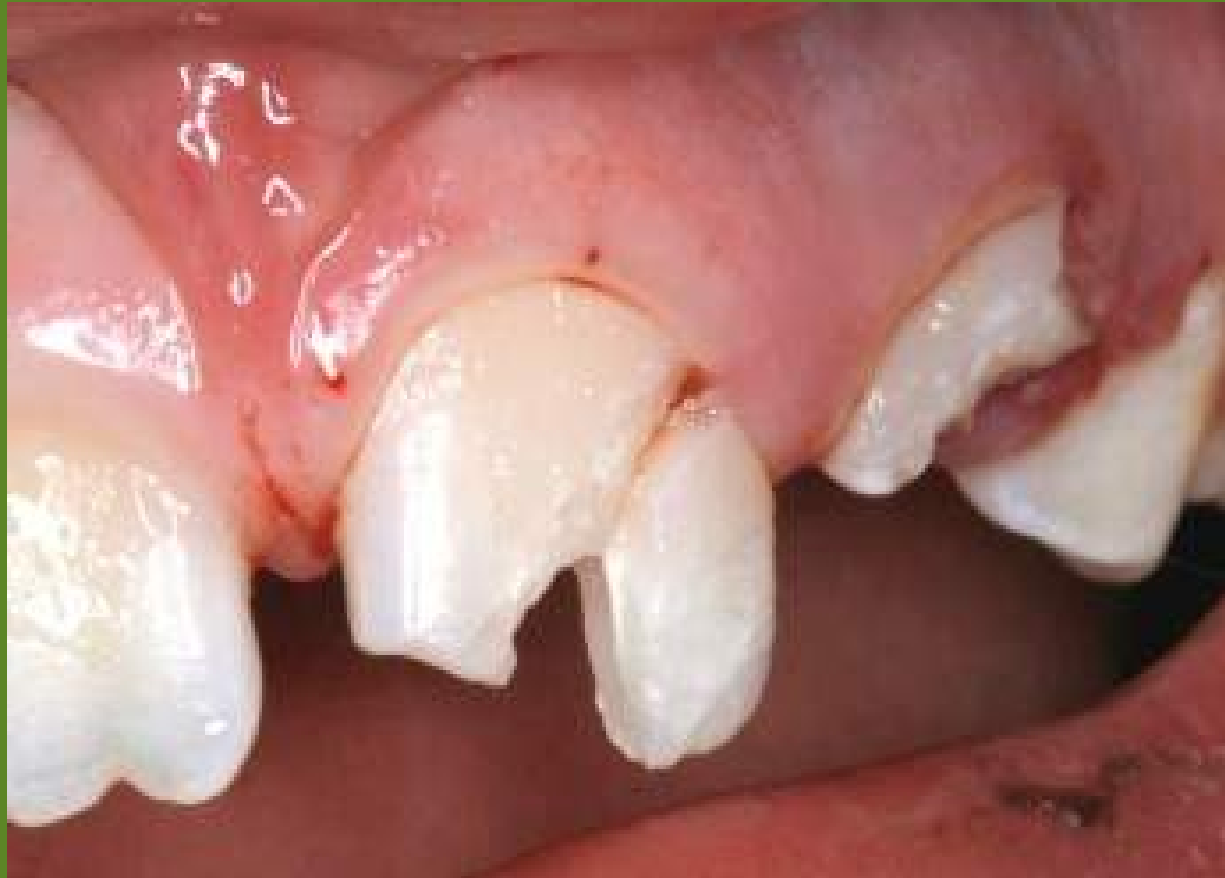# RIASSORBIMENTO RADICOLARE



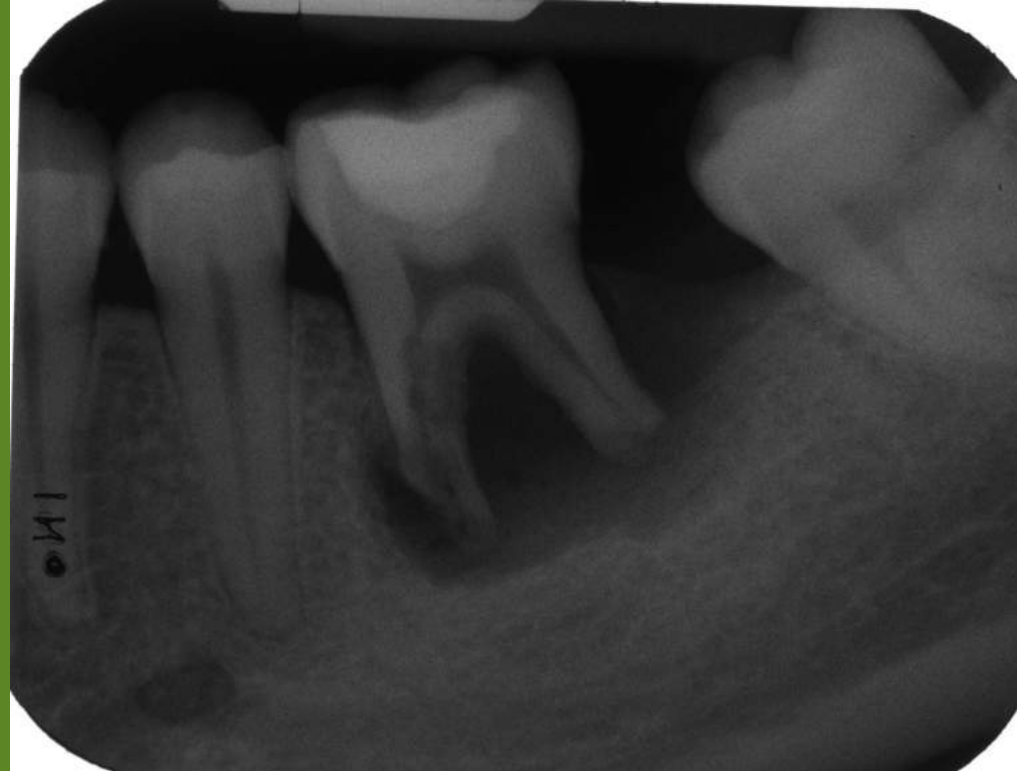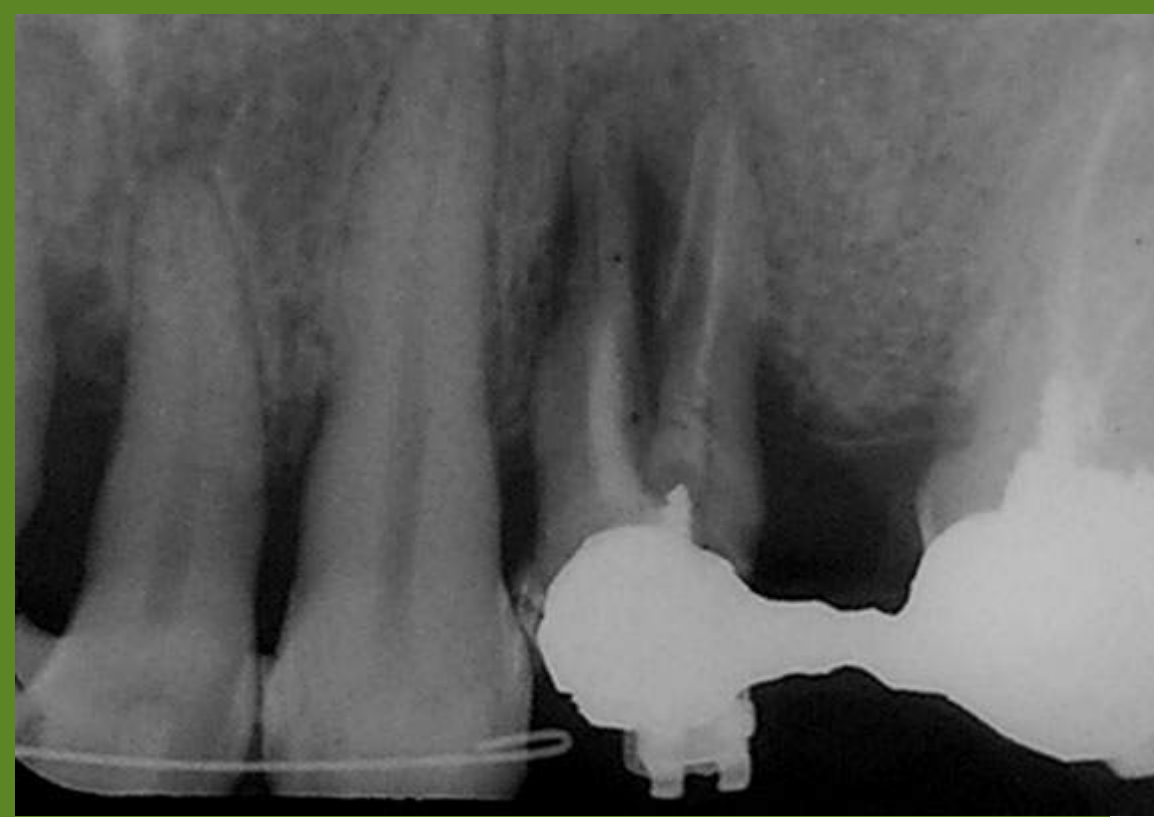# MALATTIA PARODONTALE



# TRAUMI VARI



# RADIOGRAFIA ENDORALE



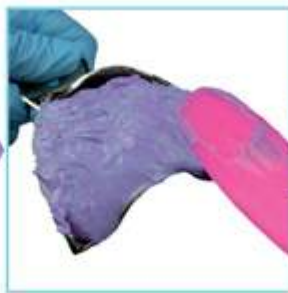

# IMPRONTE

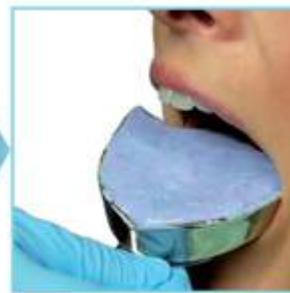- MODELLI DI STUDIO
- DIMA RADIOLOGICA PER TAC



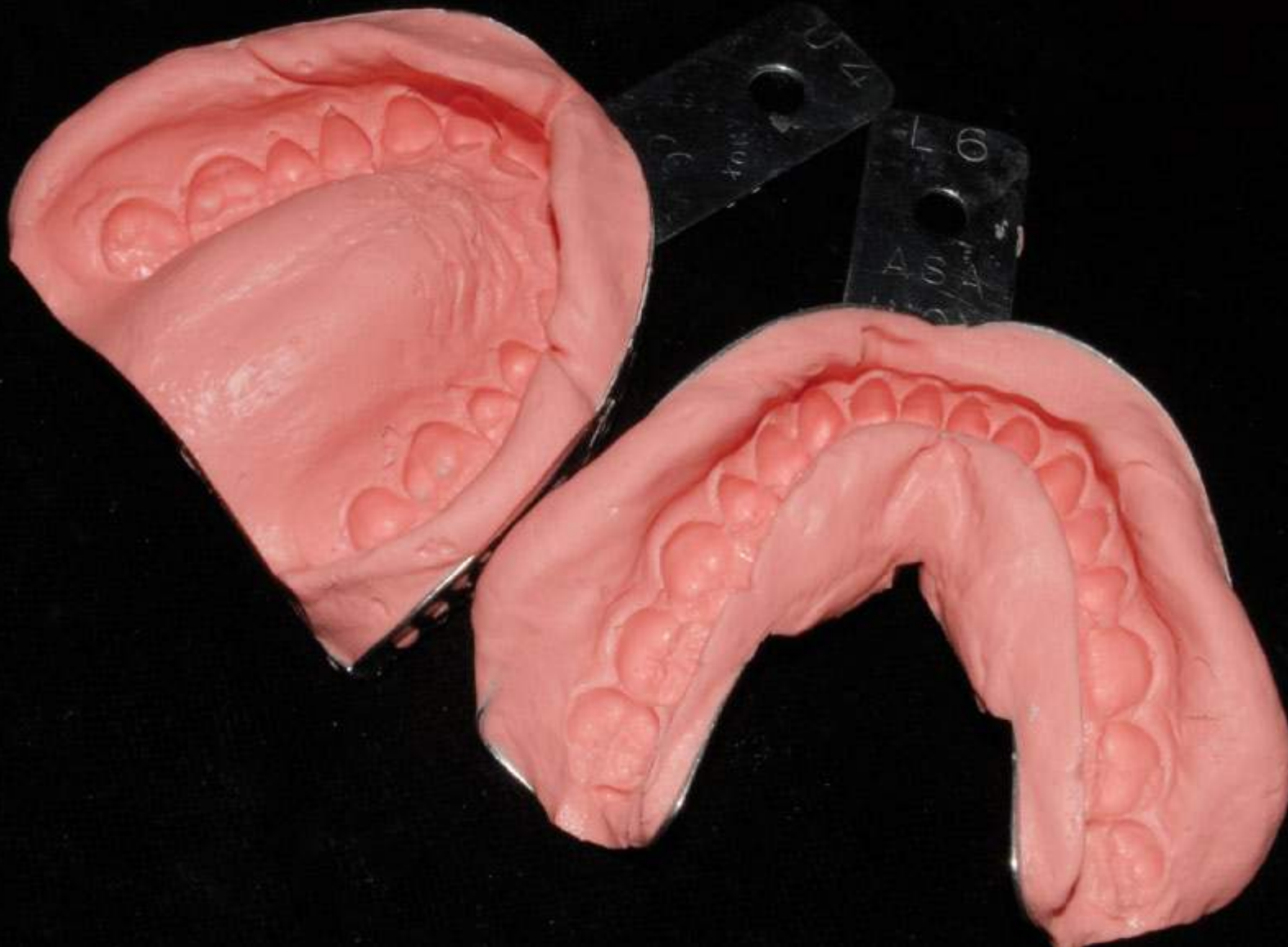Fase di miscelazione

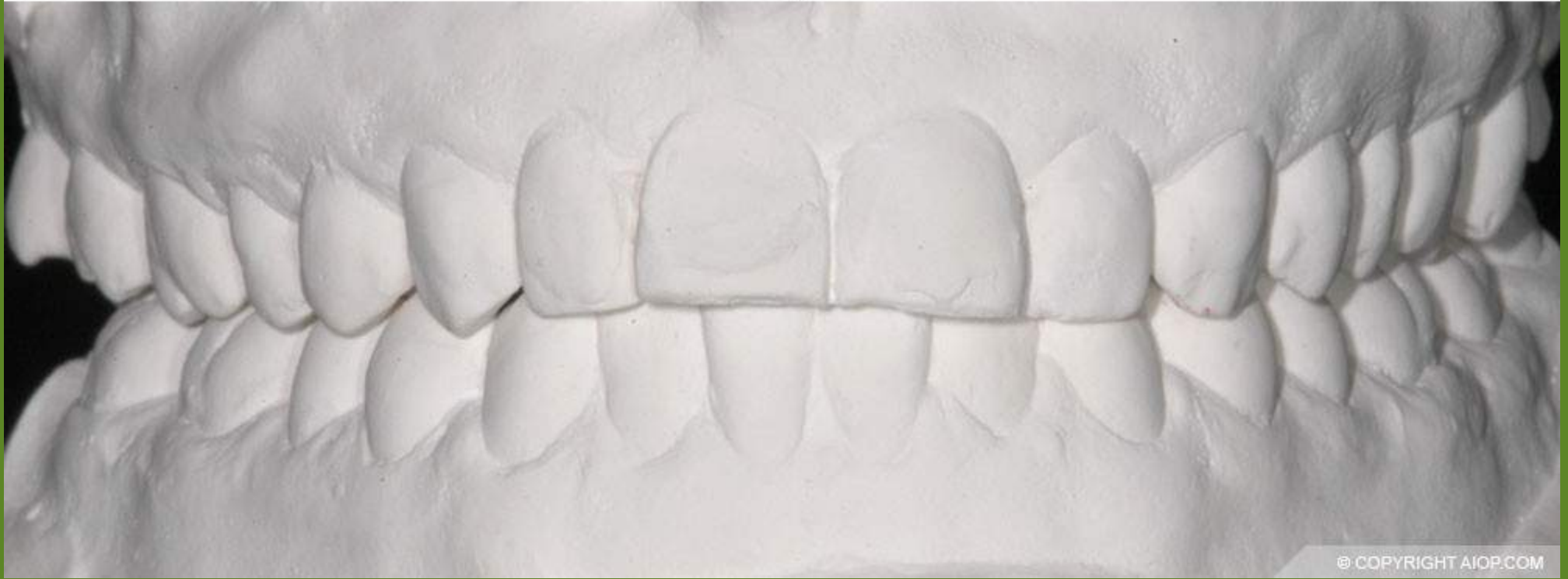
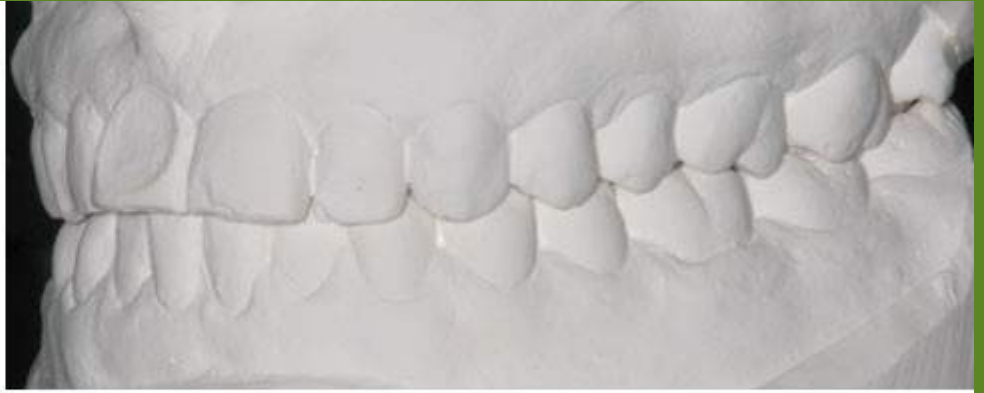
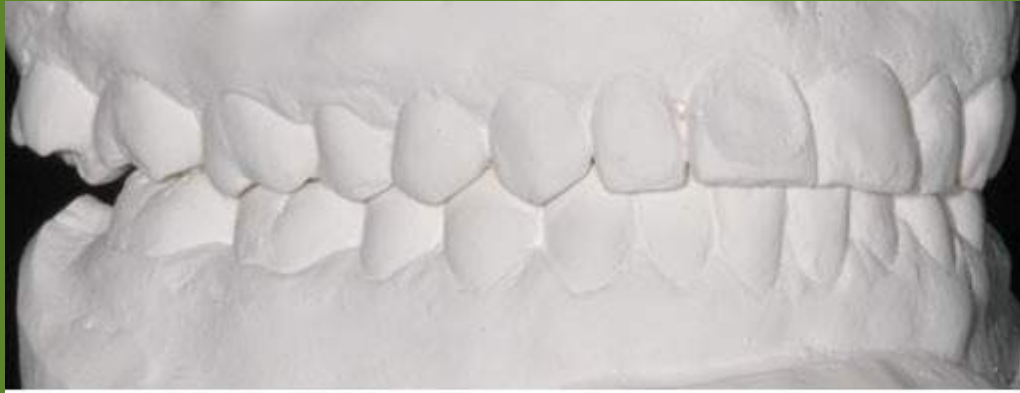Fase di lavorazione

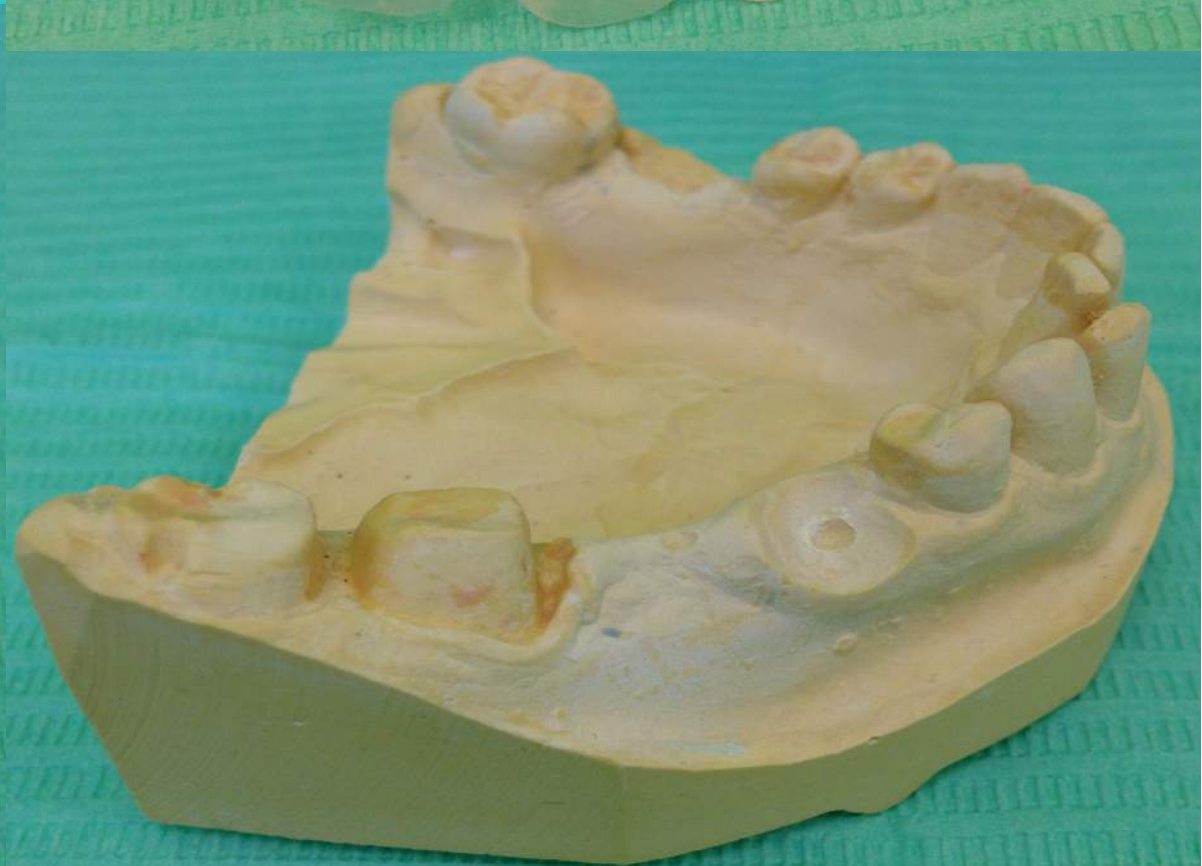
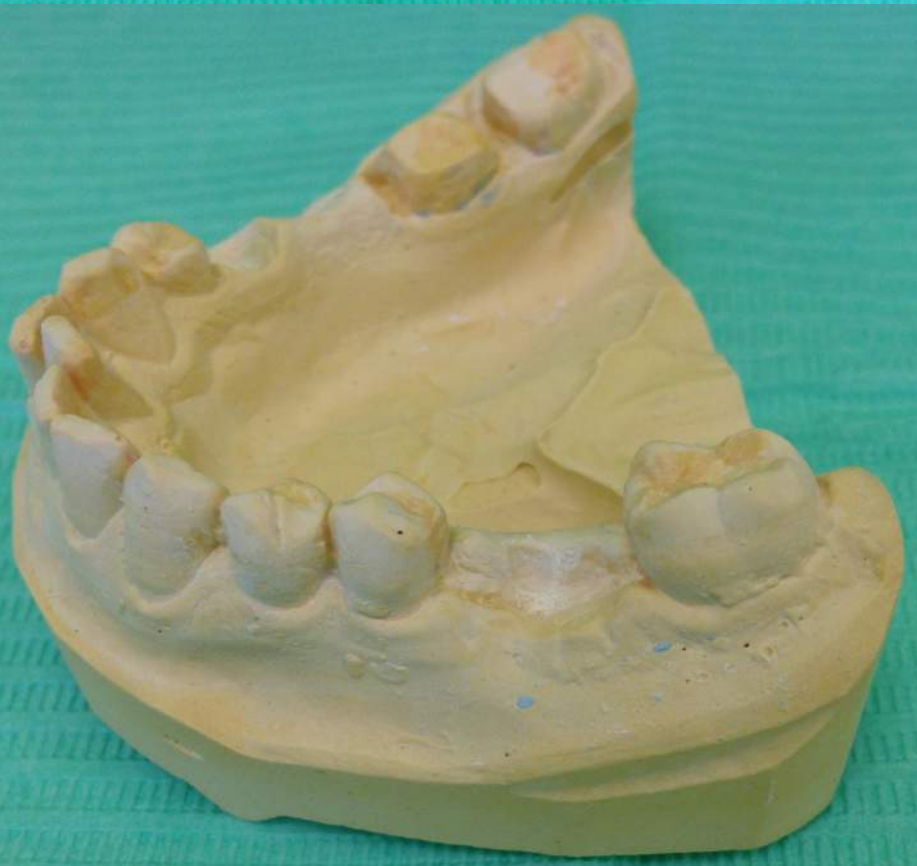
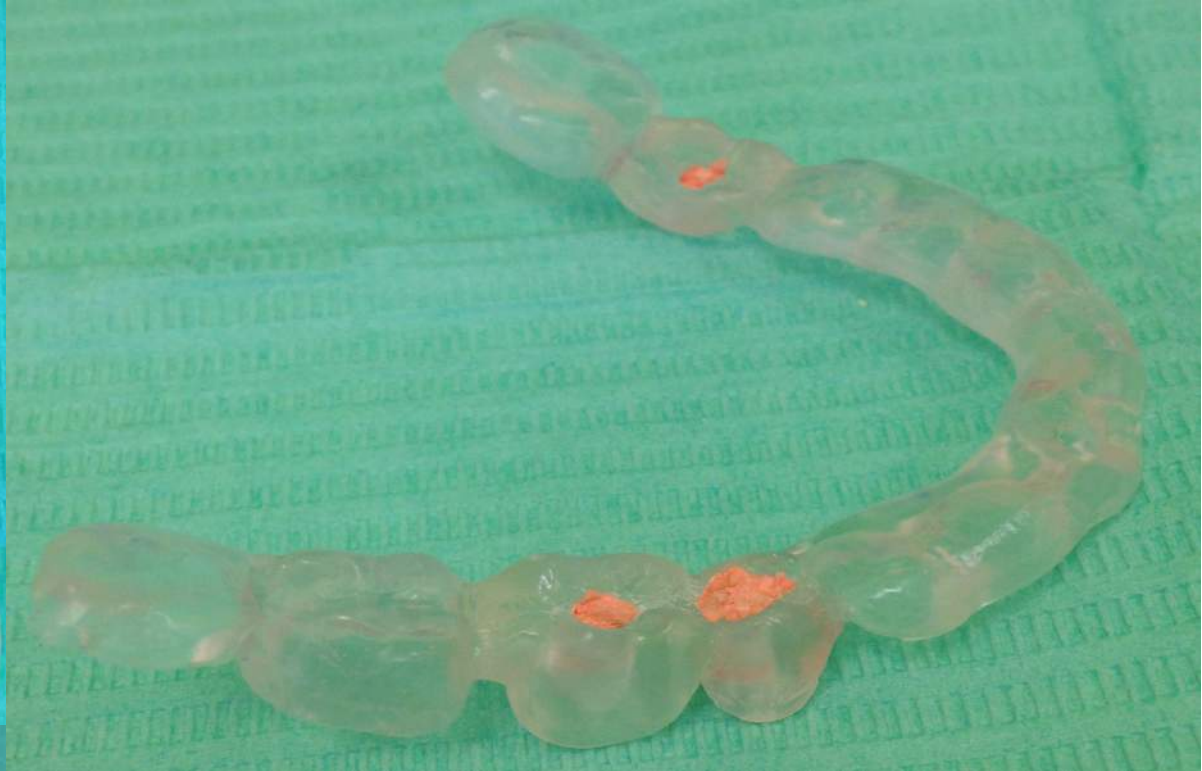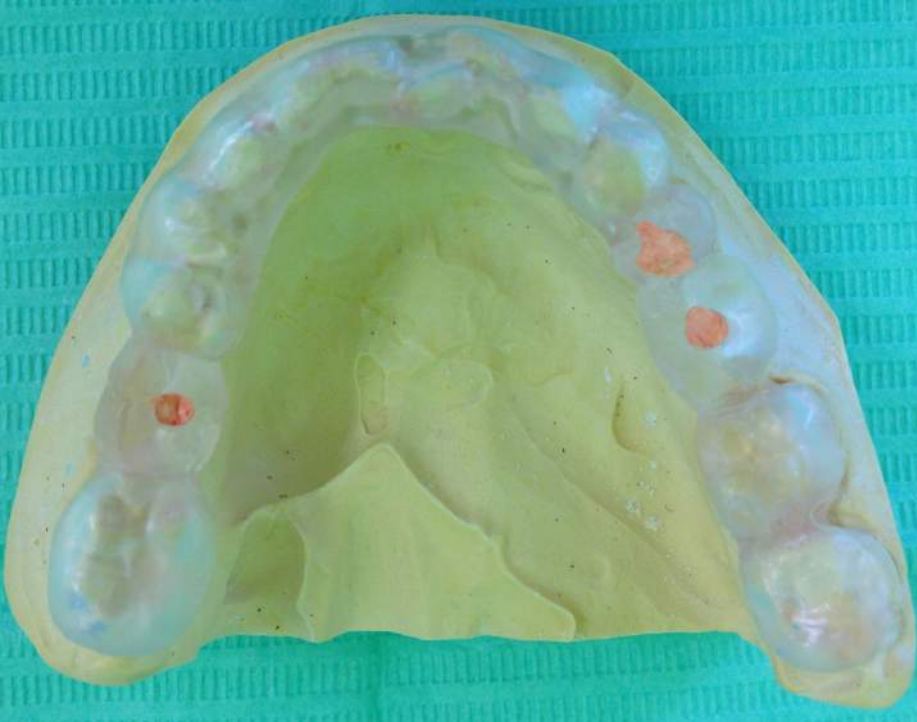Posizionamento in bocca





# DIMA RADIOLOGICA PER TC



TC DENTALE



Zoom

100%

75%

50%

153%

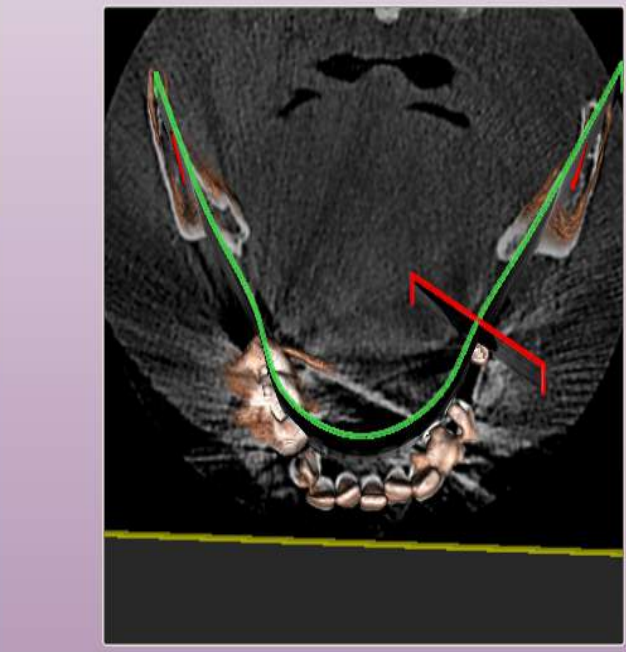
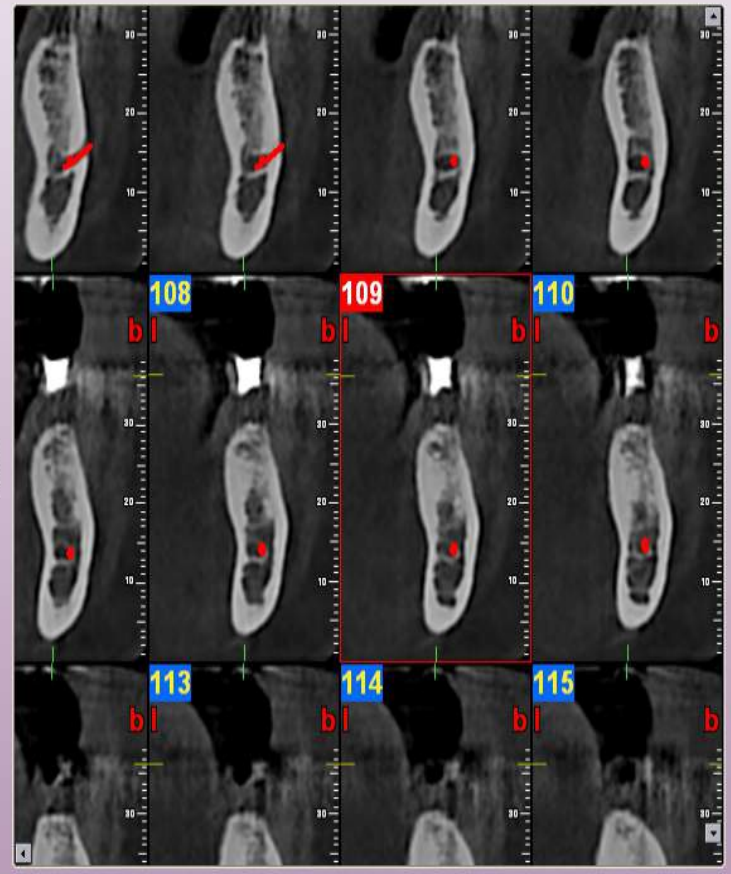
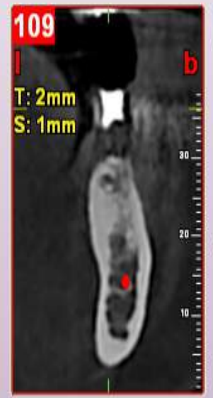
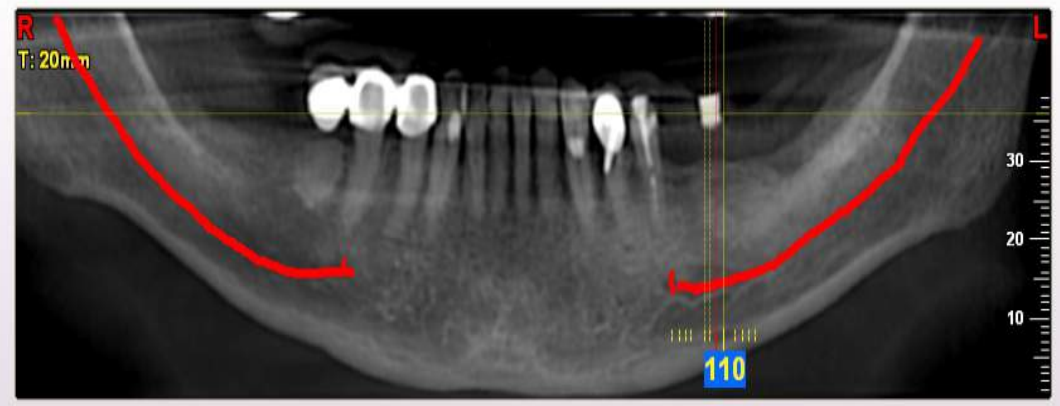
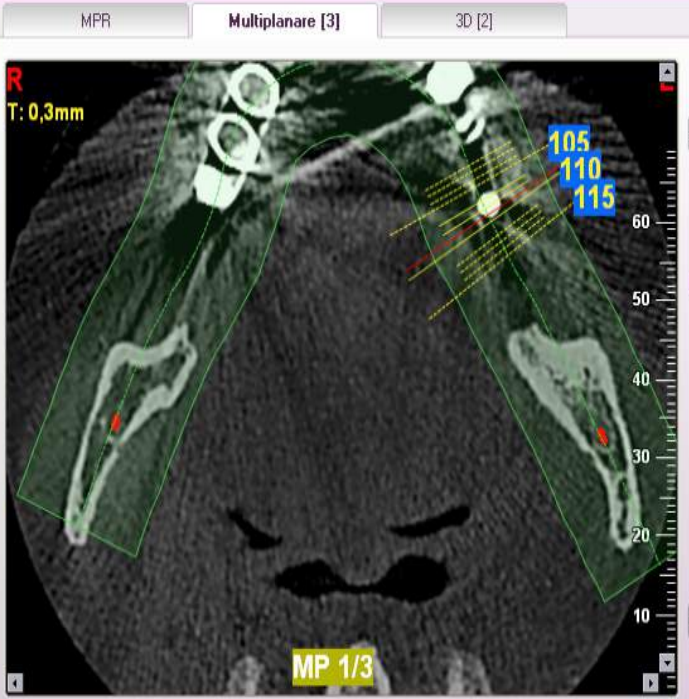
Col.: 5

Nuovo Multiplanare

Modifica

Cancella immagine(i)

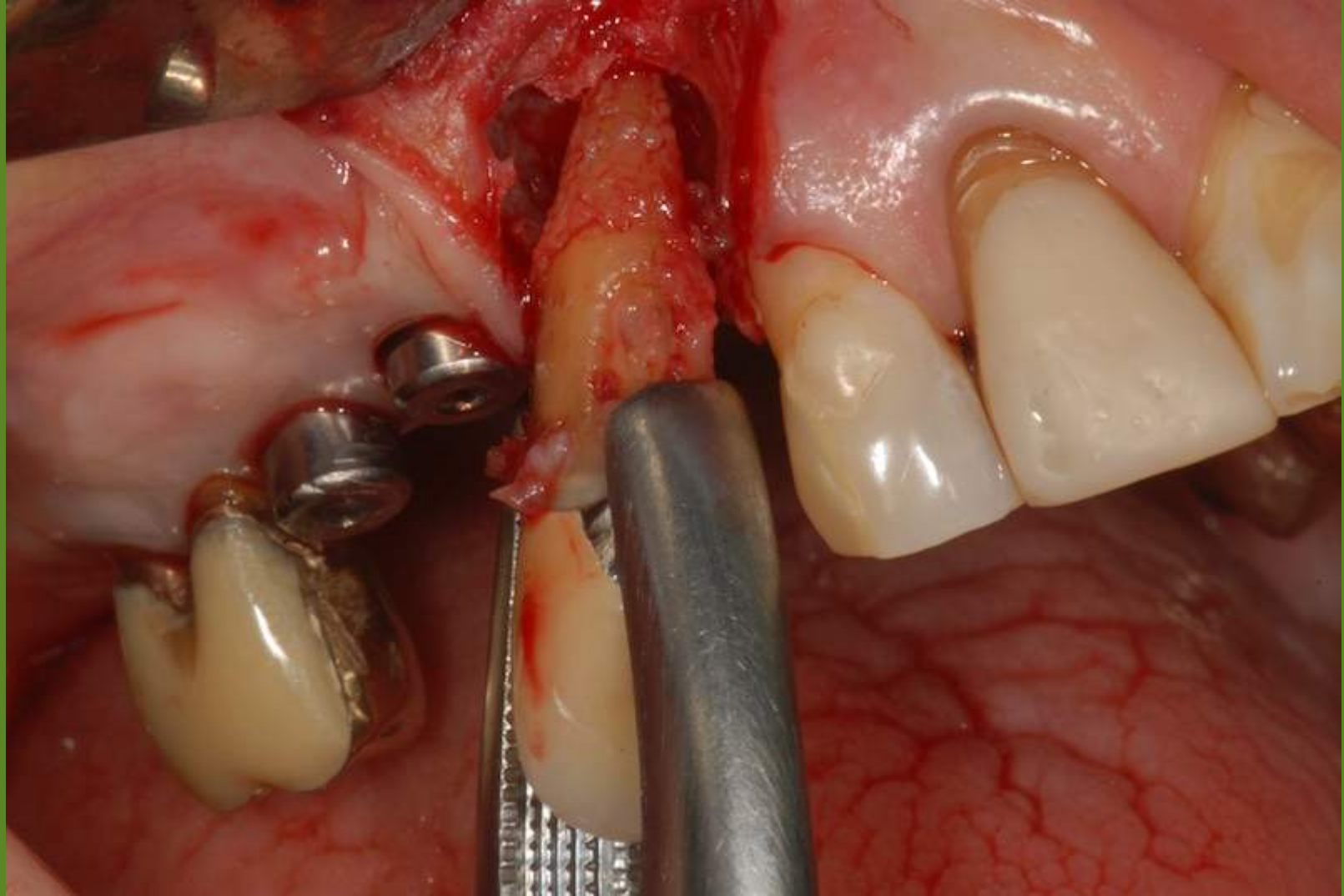
- Volume
- Rit. Ass.
- Cross
- Pan



Abilitare toolbar

**ESTRAZIONE**

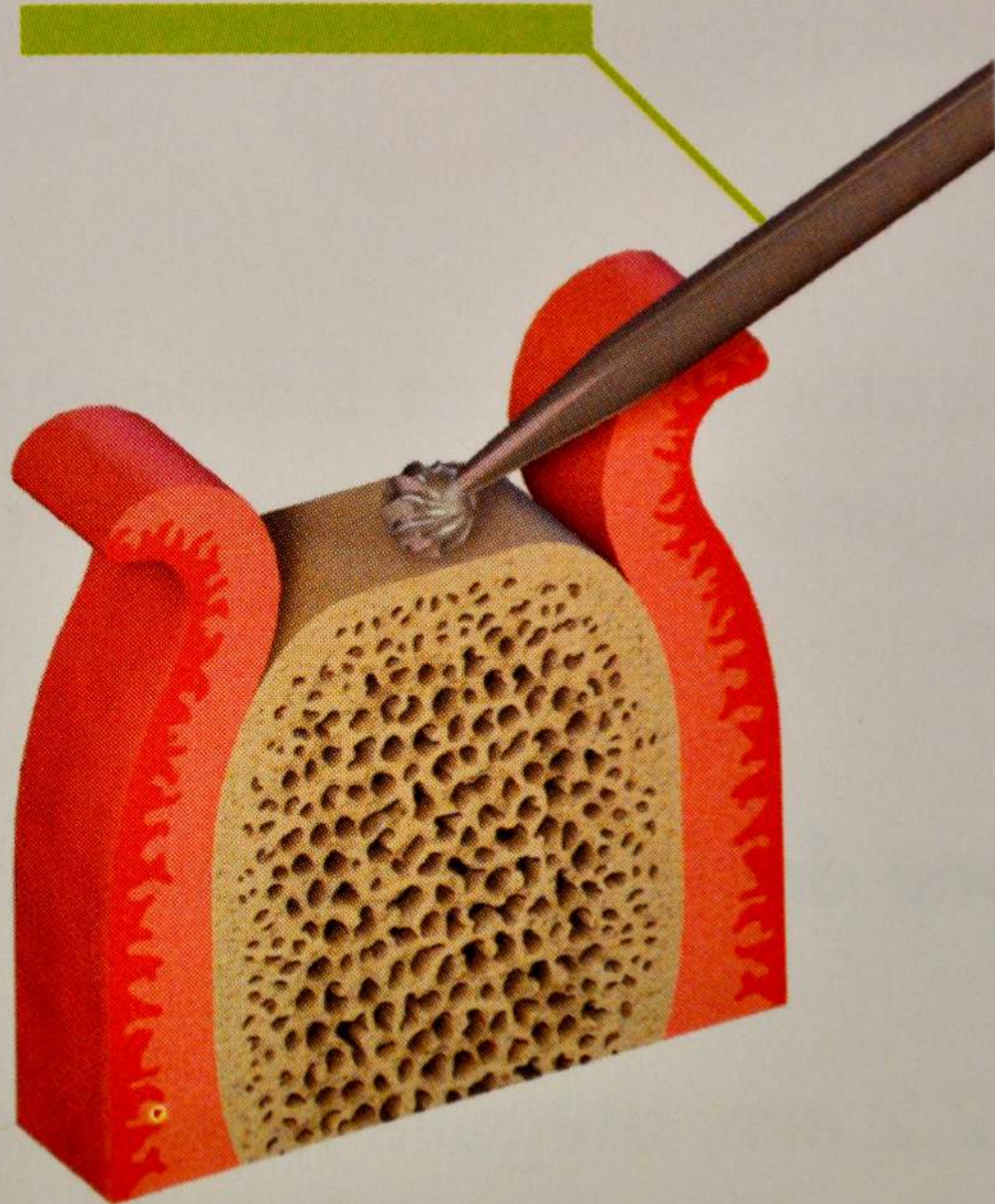




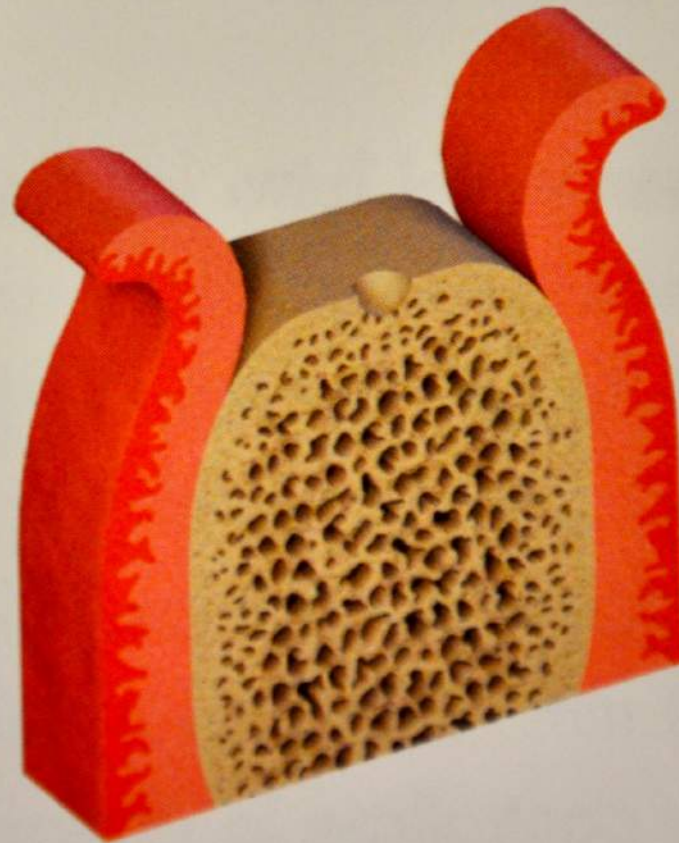
|        | TERMINOLOGIA DESCRITTIVA                          | PERIODO DOPO ESTRAZIONE | SITUAZIONE CLINICA ALL'INSERIMENTO IMPLANTARE                  |
|--------|---|-------------------------|--|
| TIPO 1 | POSIZIONAMENTO IMMEDIATO                          | 0                       | SITO SENZA GUARIGIONE OSSEA E TISSUTALE                        |
| TIPO 2 | INSERIMENTO PRECOCE CON GUARIGIONE DEI TESSUTI    | 4/8 SETTIMANE           | SITO CON GUARIGIONE TISSUTALE E SCARSA GUARIGIONE OSSEA        |
| TIPO 3 | INSERIMENTO PRECOCE CON PARZIALE GUARIGIONE OSSEA | 12/16 SETTIMANE         | SITO CON GUARIGIONE TISSUTALE E SIGNIFICATIVA GUARIGIONE OSSEA |
| TIPO 4 | INSERIMENTO RITARDATO                             | 6 MESI CIRCA O PIU'     | COMPLETA GUARIGIONE DEL SITO POST- ESTRATTIVO                  |

FASE CHIRURGICA

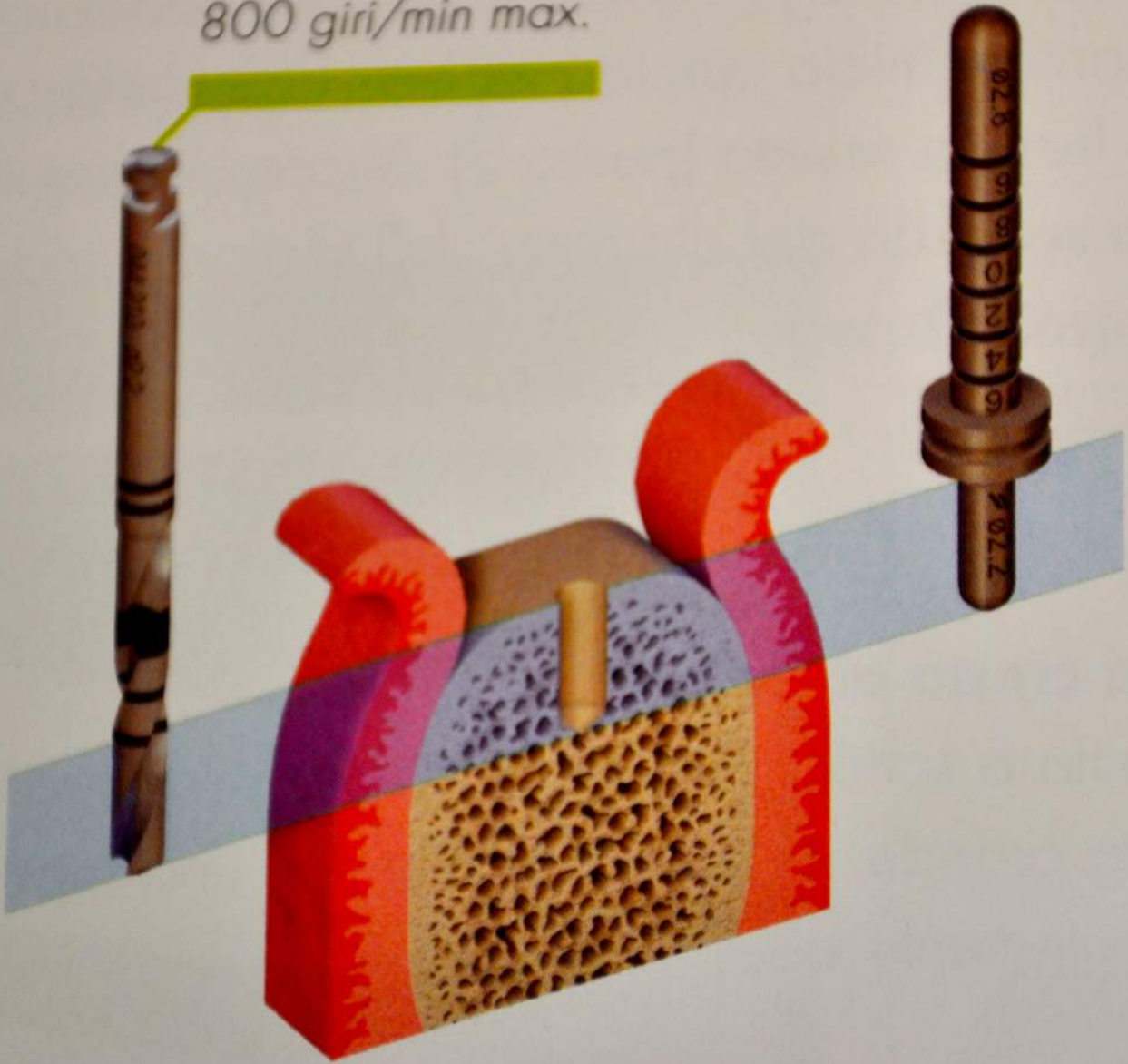
800 giri/min max.



800 giri/min max.




800 giri/min max.



800 giri/min max.

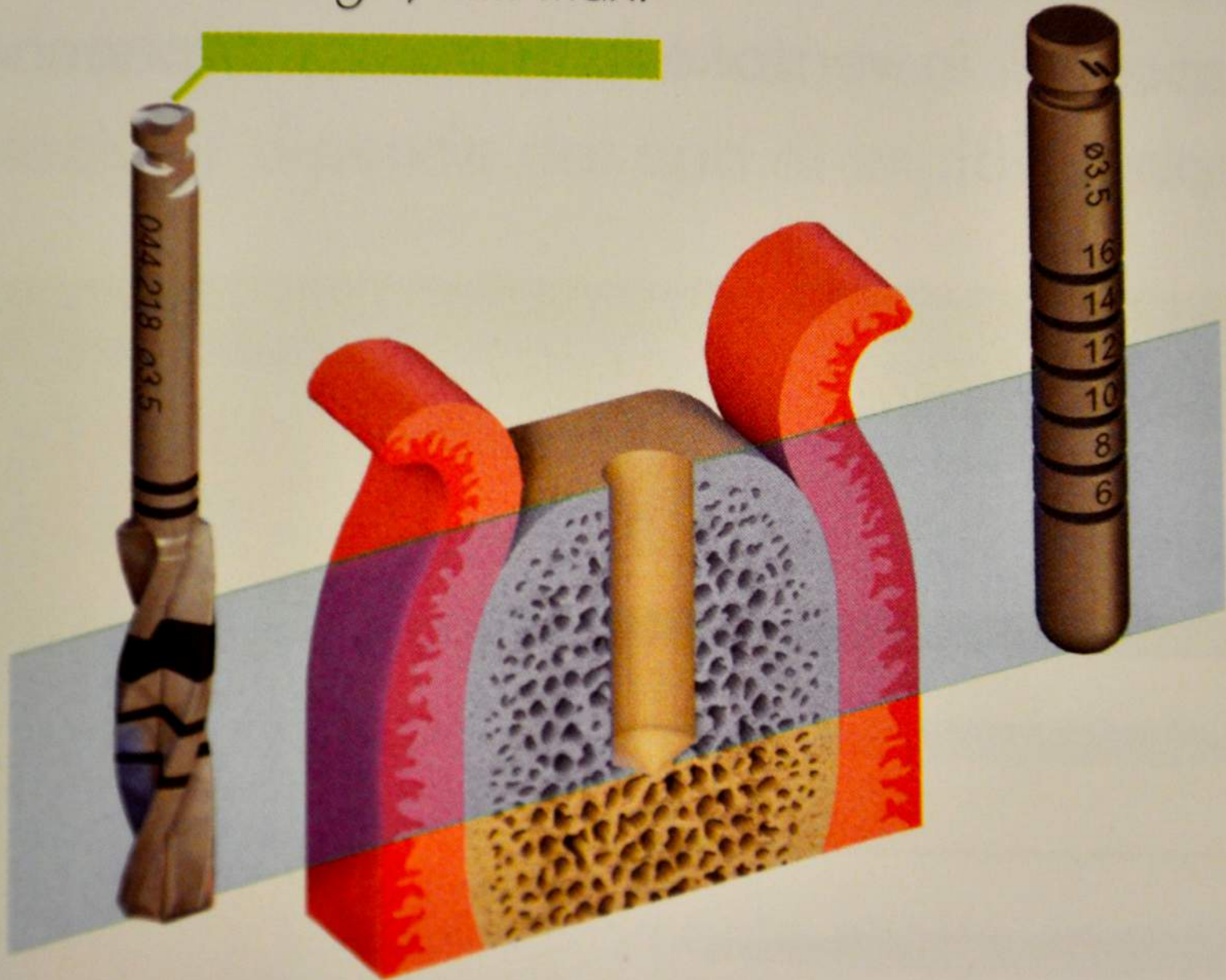


600 giri/min max.



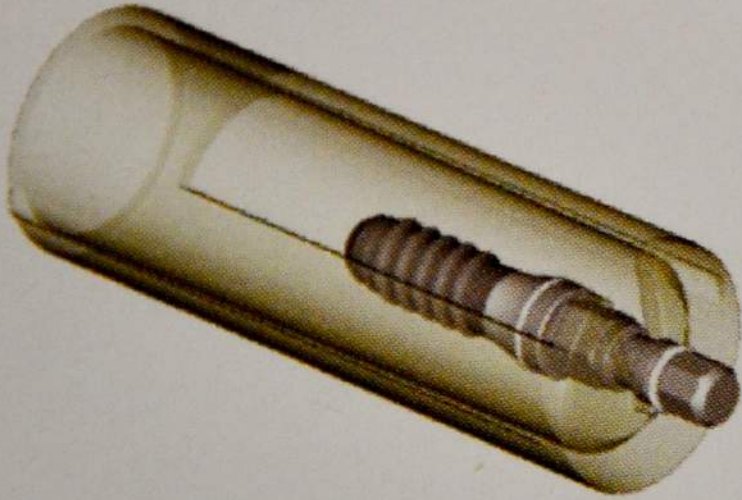

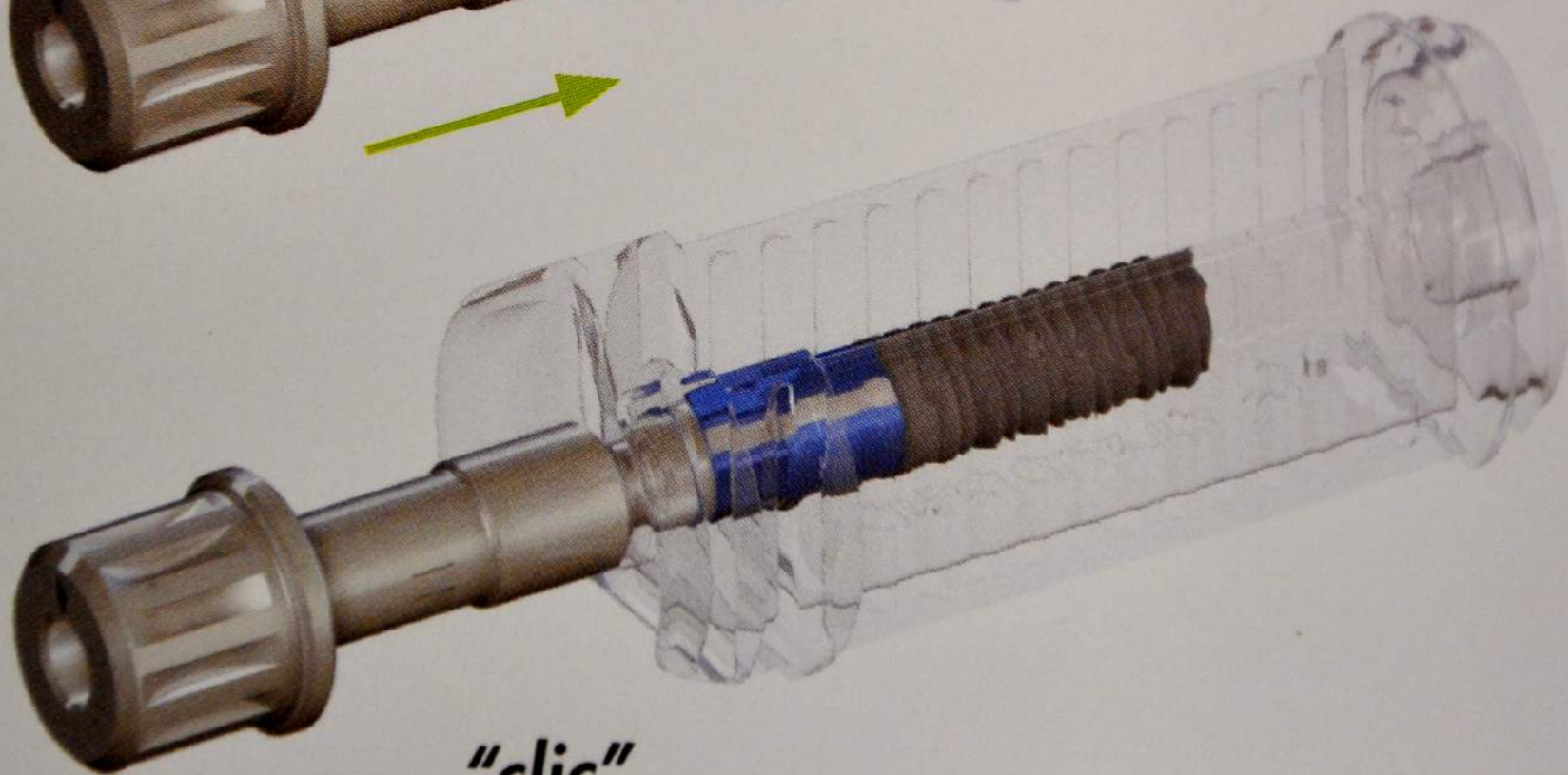
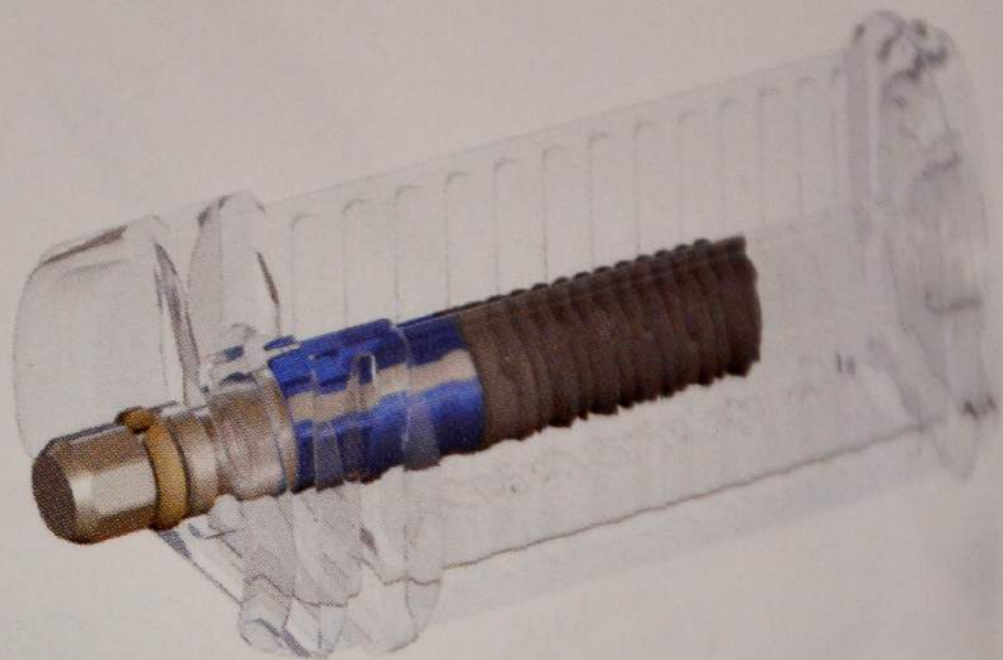

500 giri/min max.



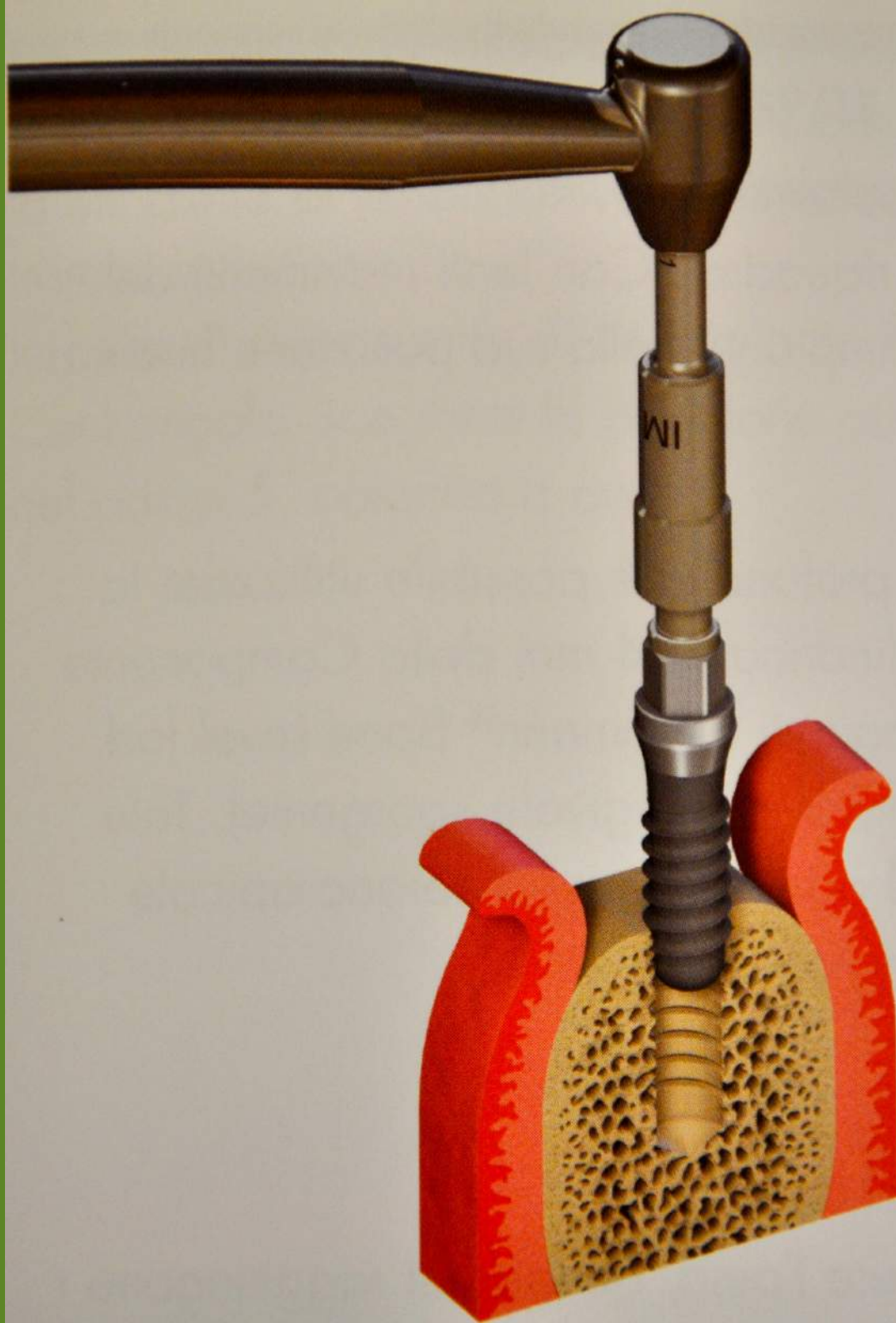
400 giri/min max.

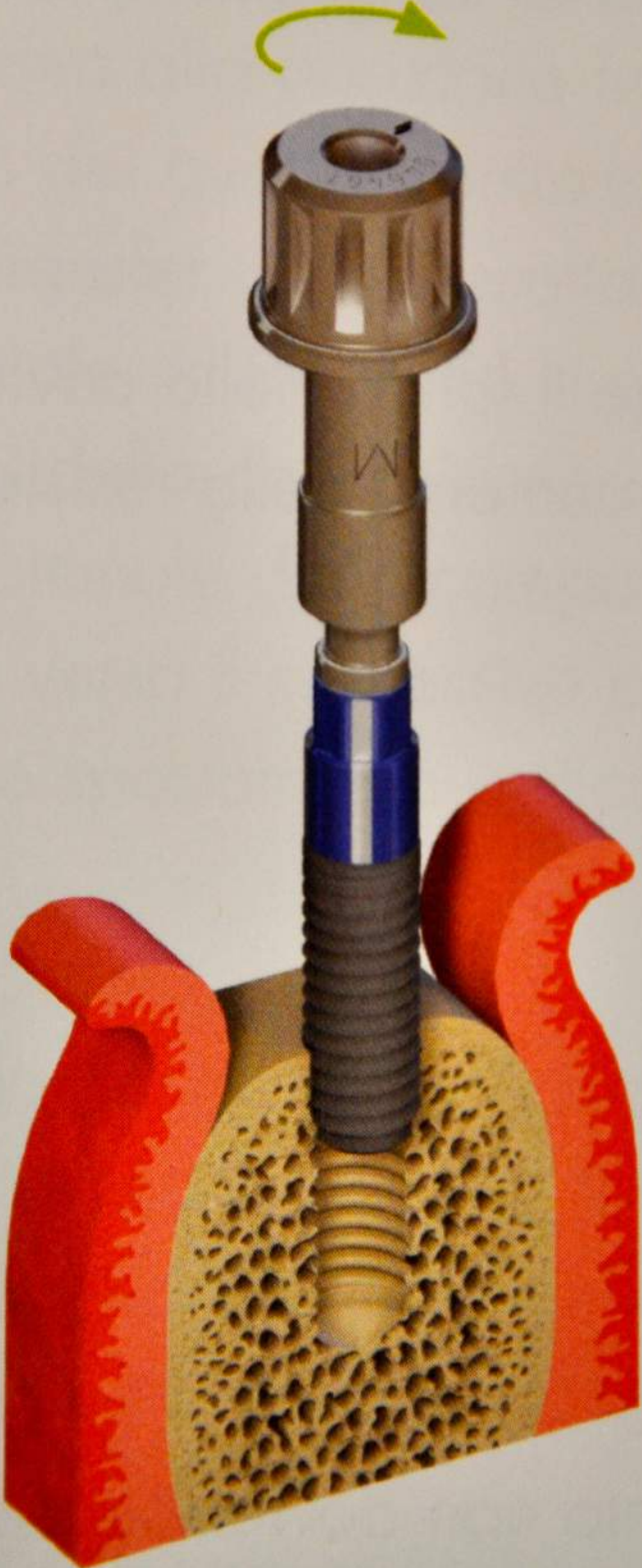


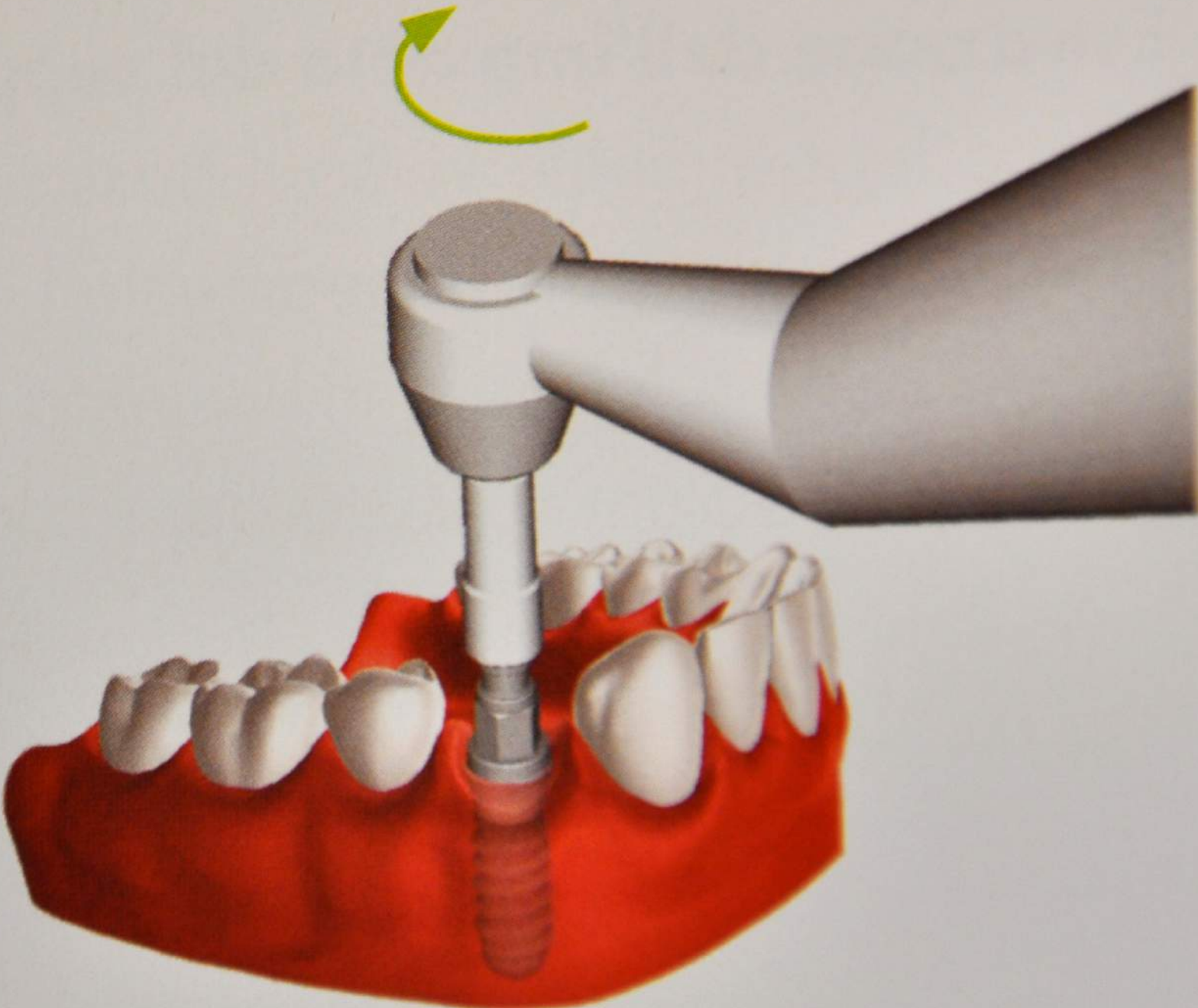


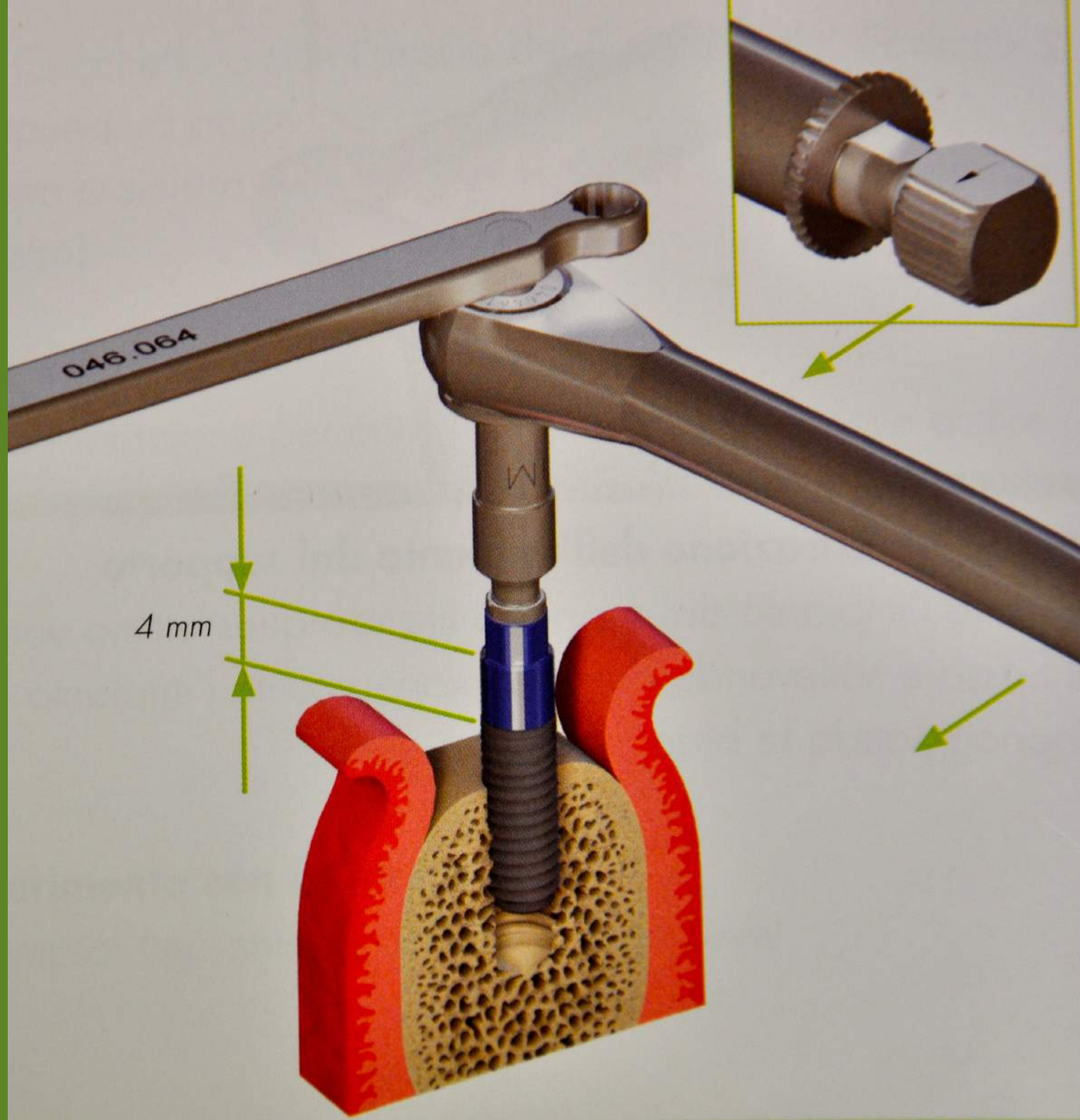


**"clic"**

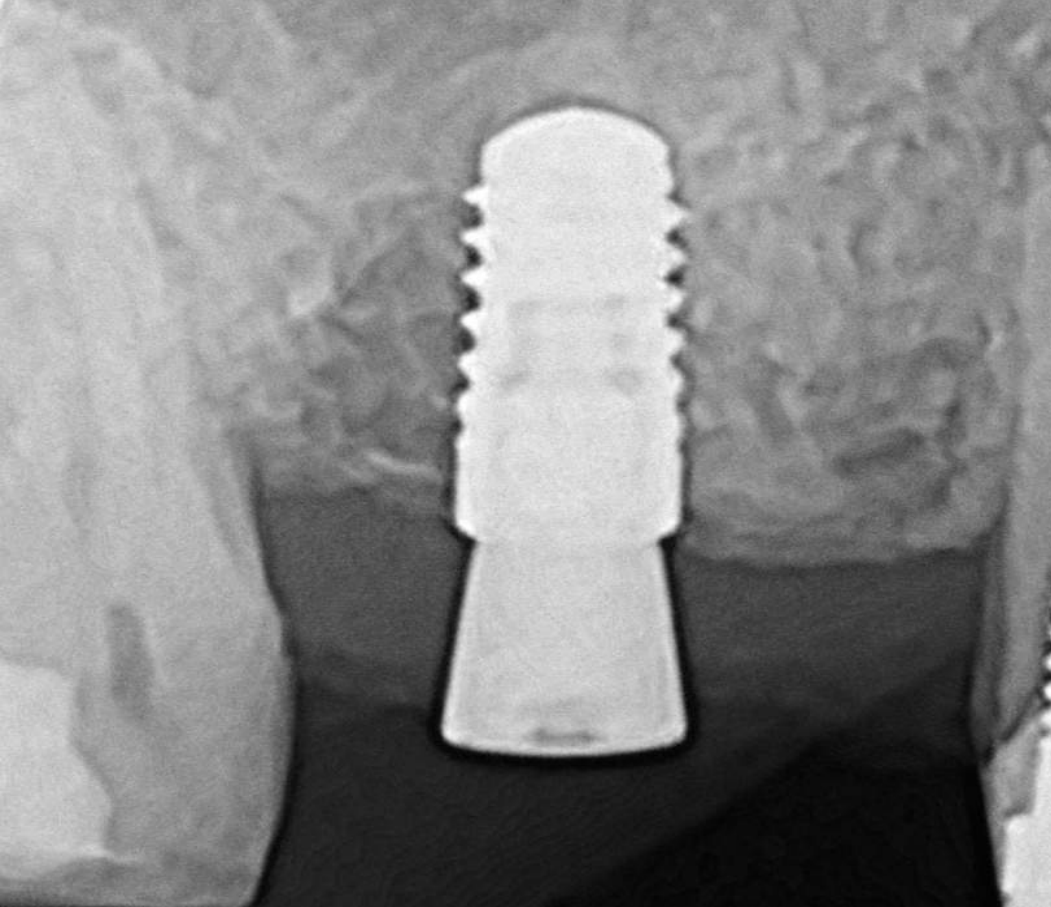












FASE PROTESICA



